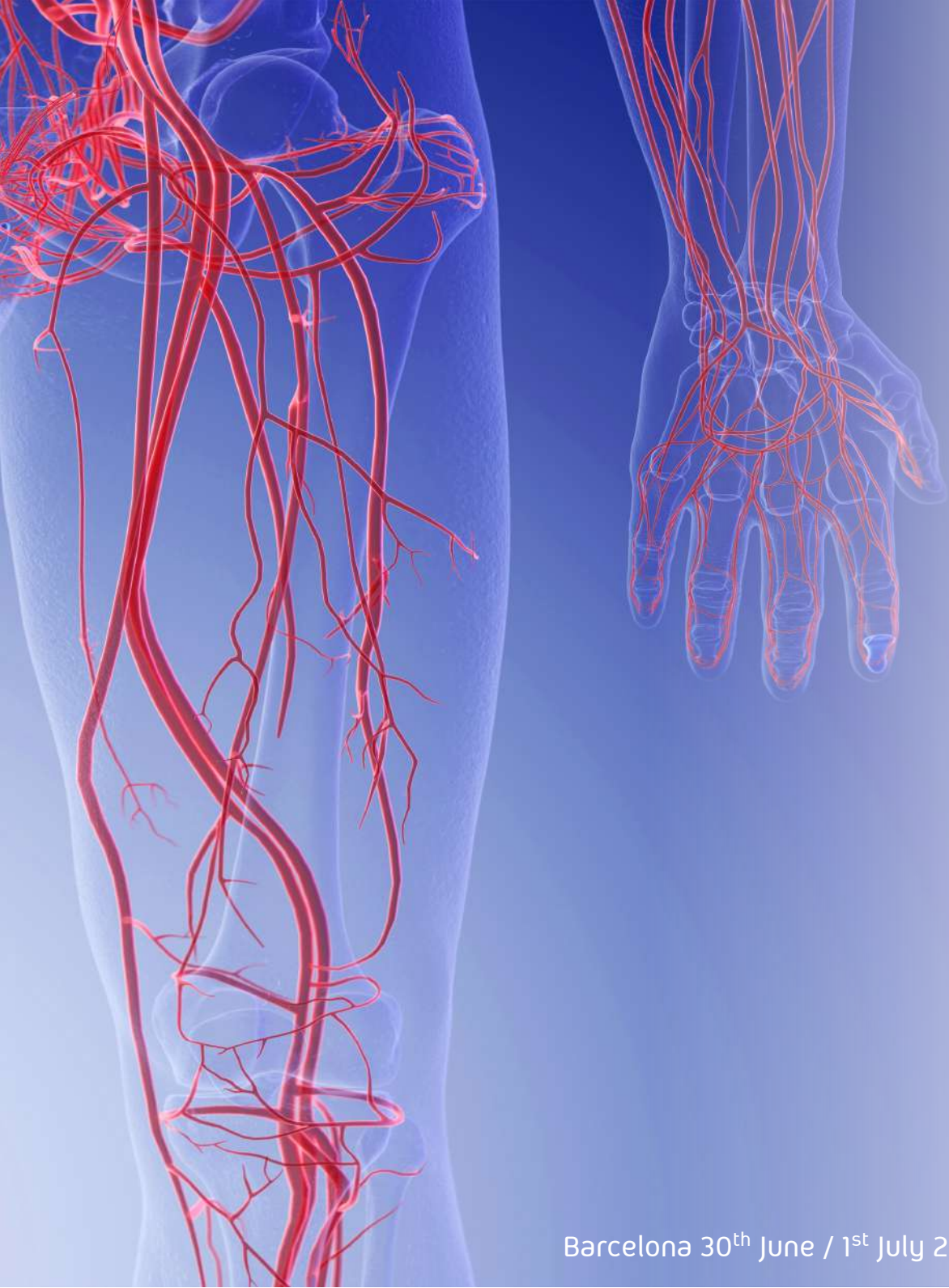

# iVS

interactive Vascular Summit

## Case

Fabrizio Fanelli, MD, EBIR, FCIRSE

Director Vascular and Interventional Radiology Department

“Careggi” University Hospital

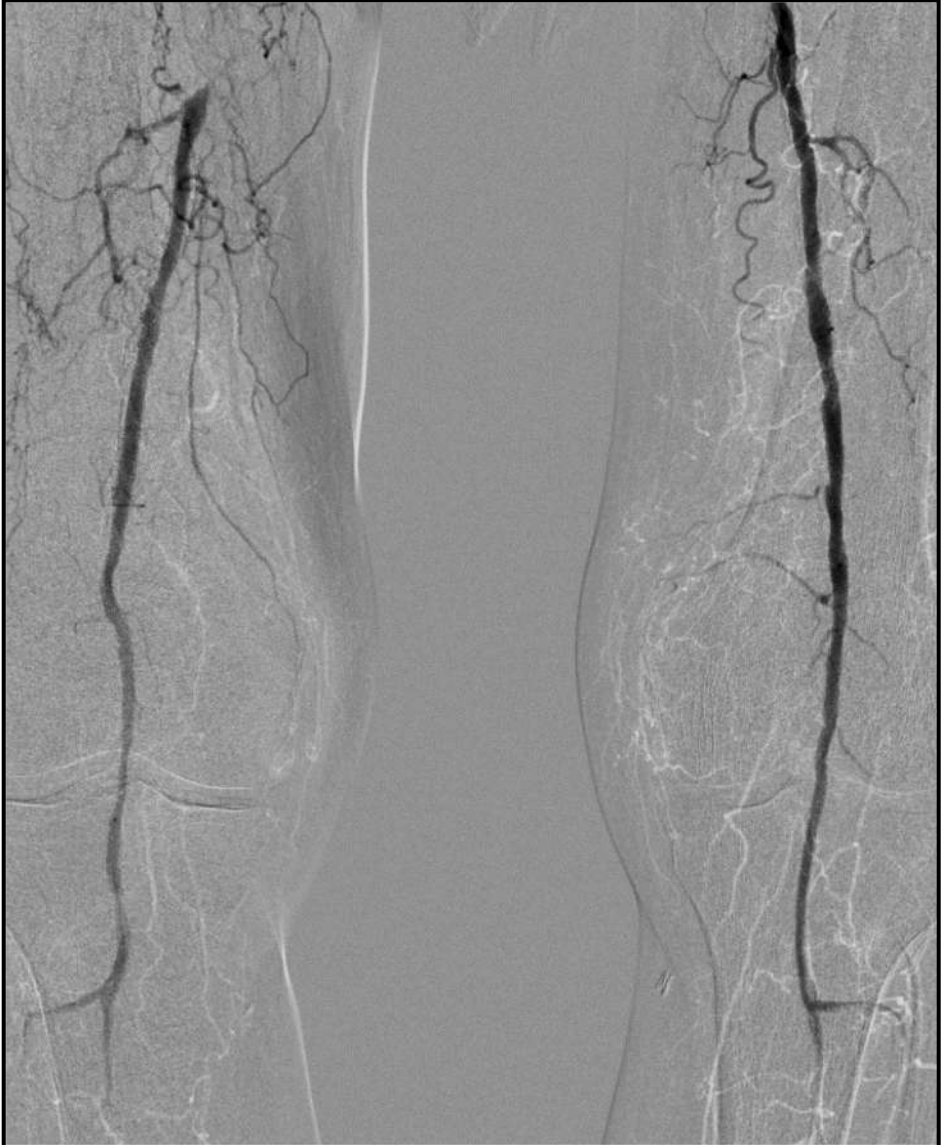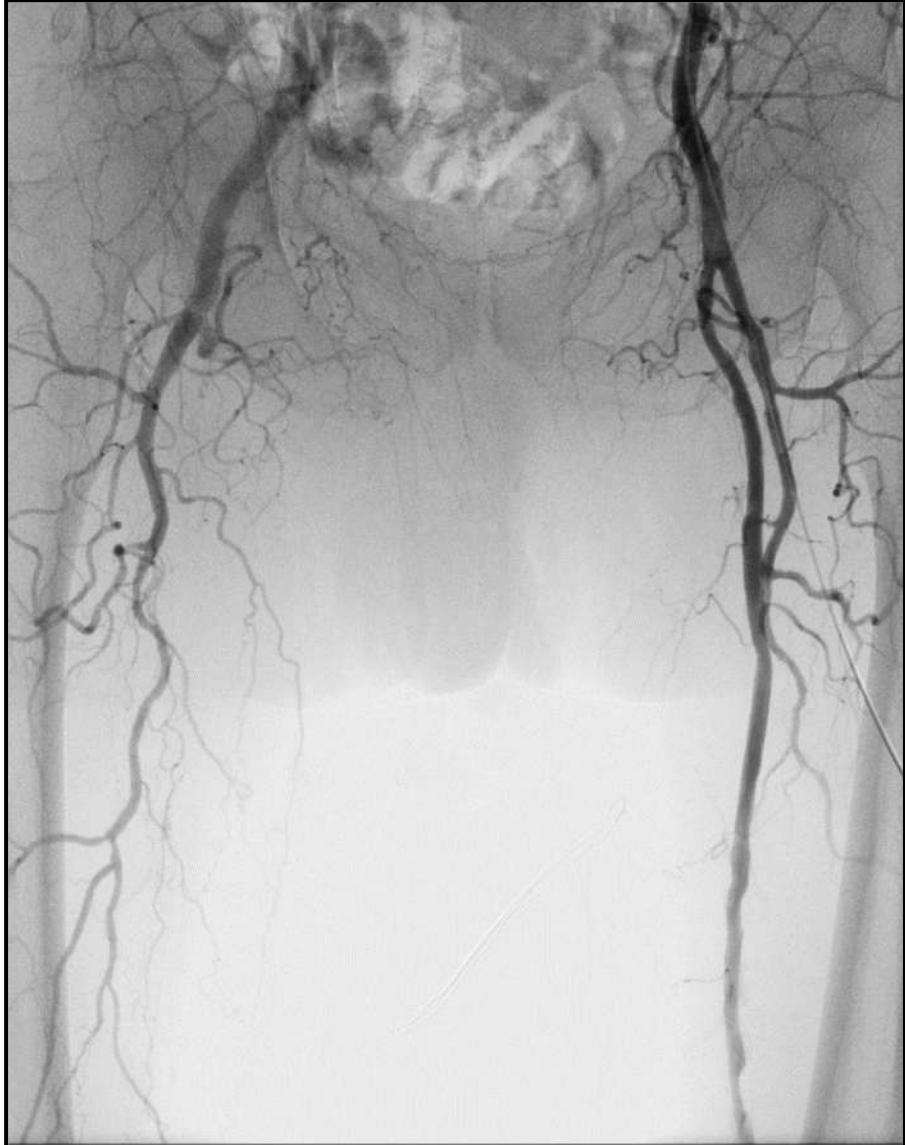Florence - Italy

Barcelona 30<sup>th</sup> June / 1<sup>st</sup> July 2022

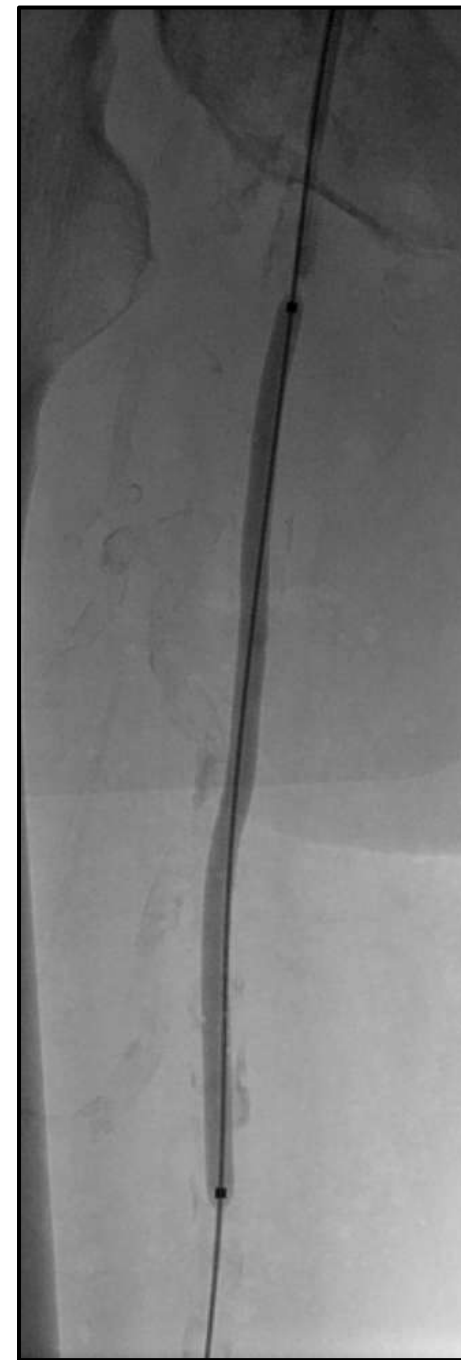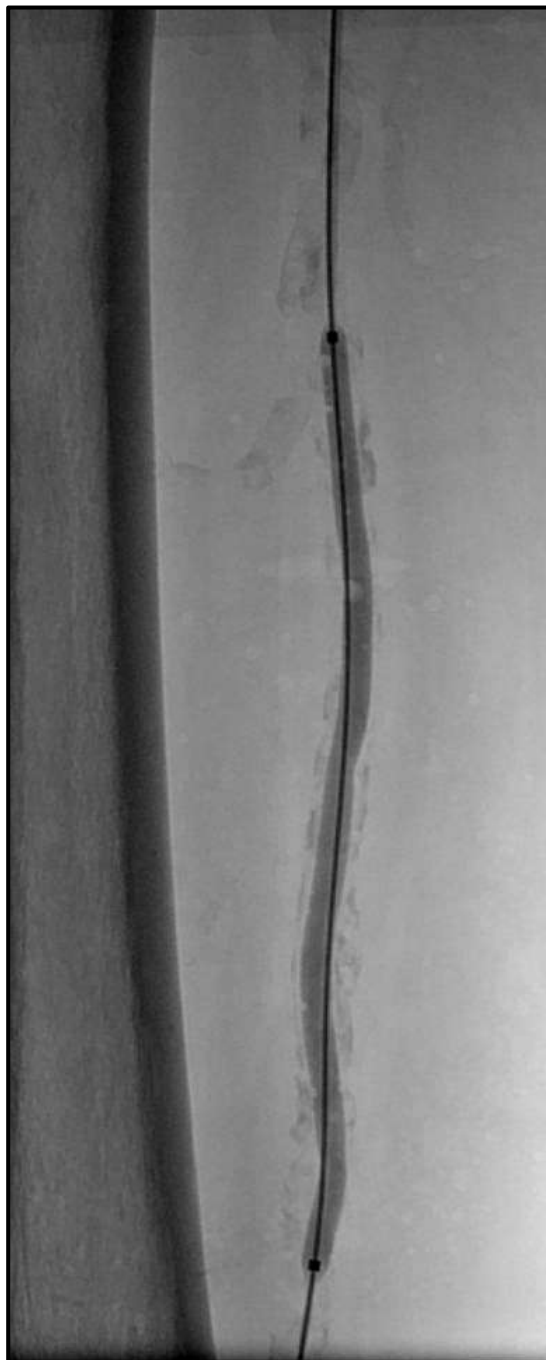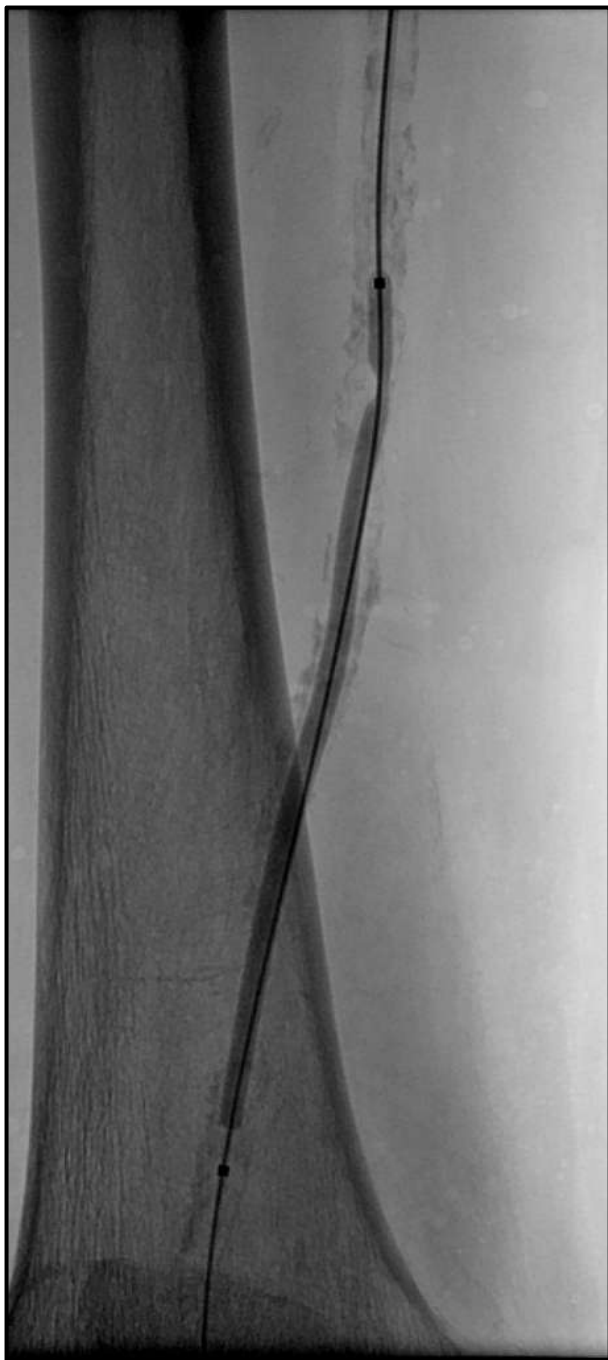**iVascular**  
therapies for living

D.G. 67-y. Male  
Heavy smoker, hypertension  
Right <50 mt claudication

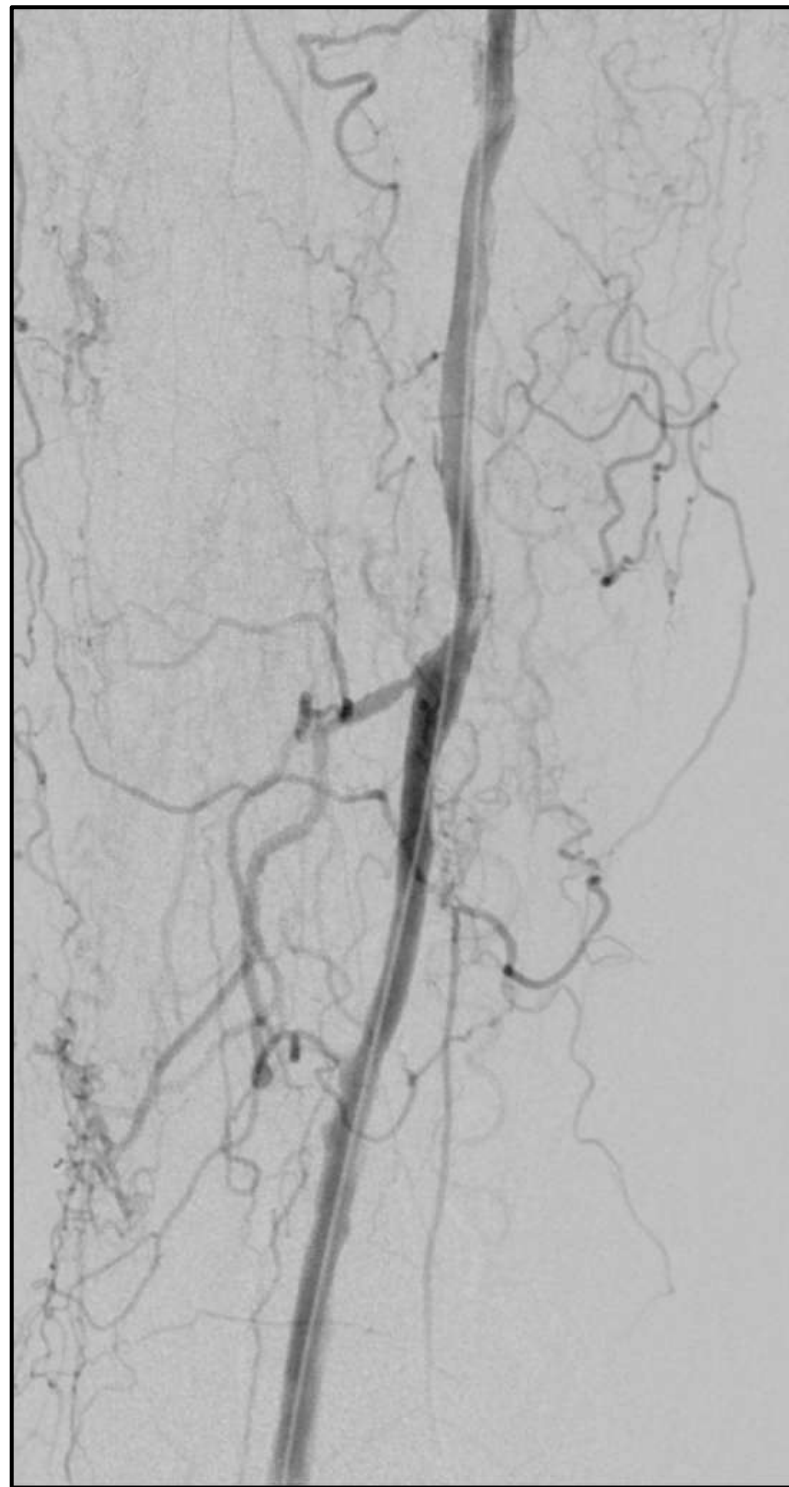
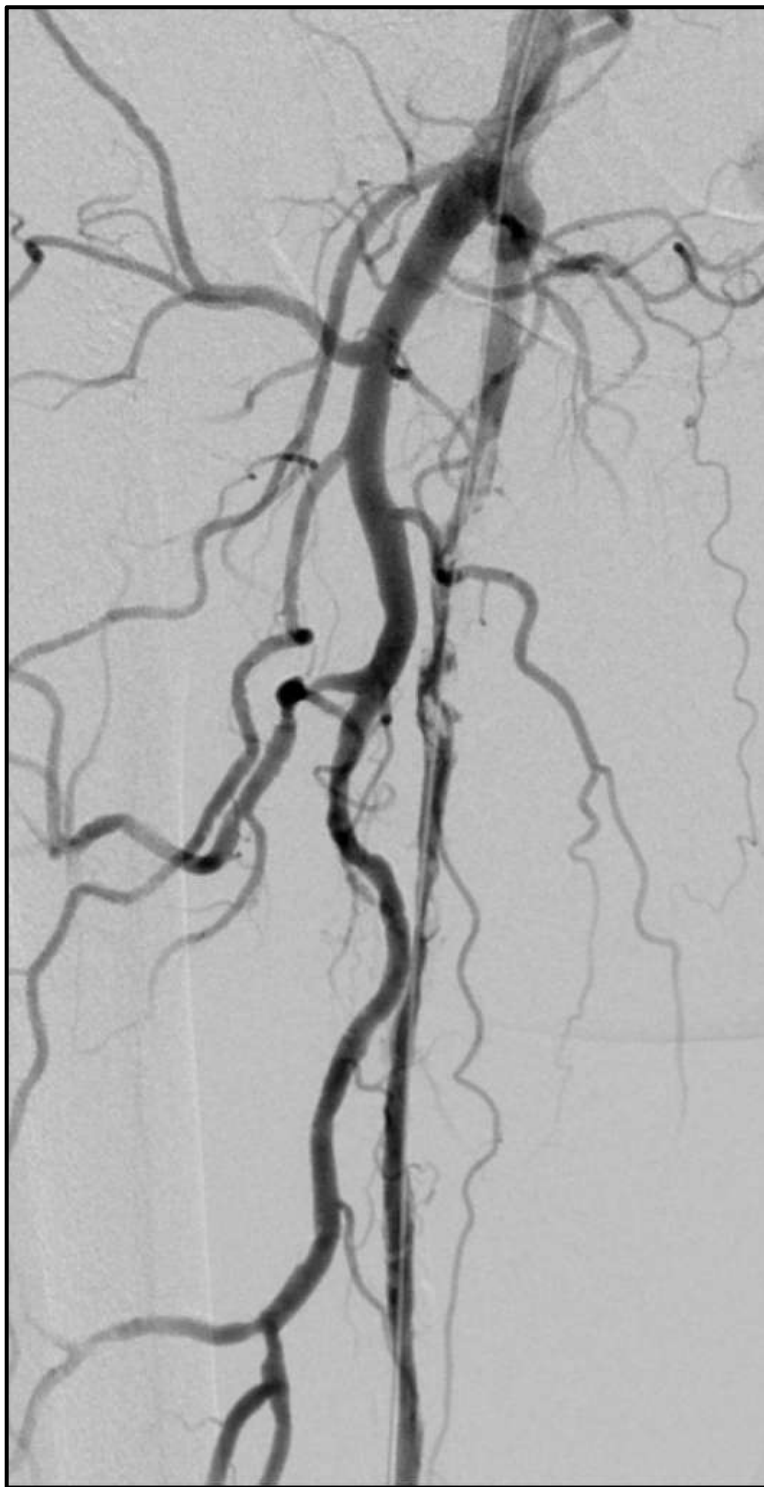
USCD: Occlusion of the Rt SFA



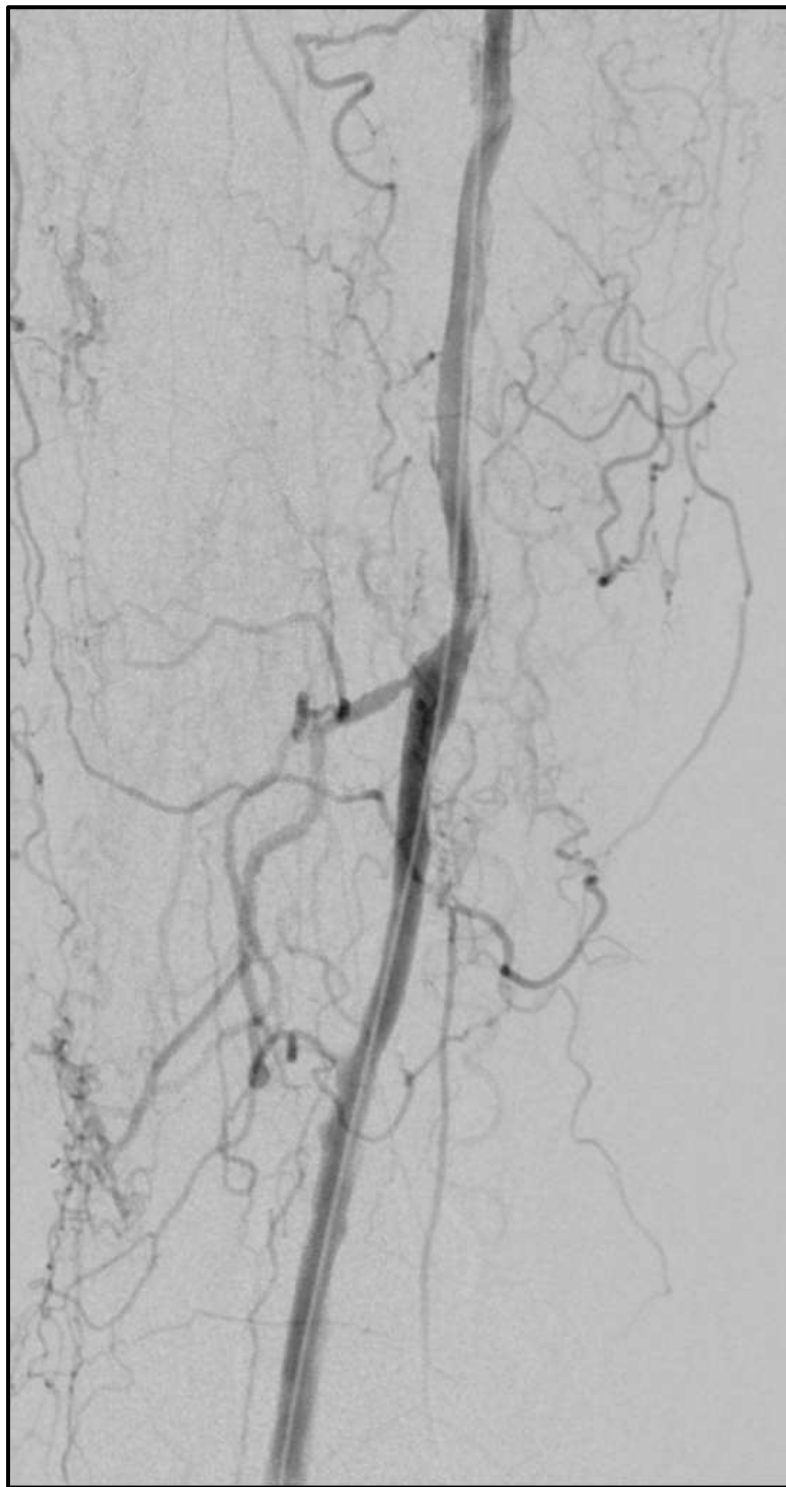
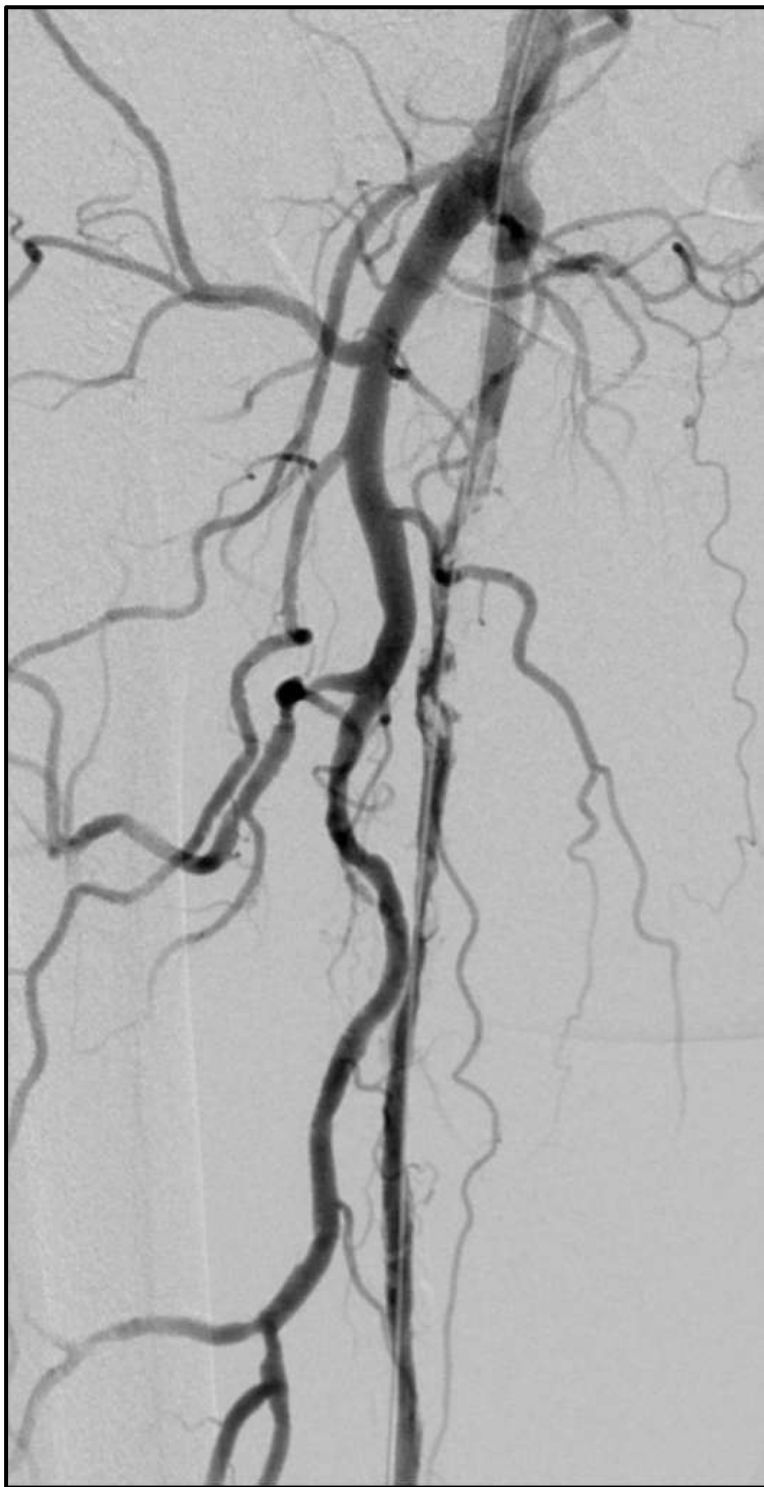
4 FR. Support catheter  
.35» hydrophilic guidewire



4 mm  
PTA



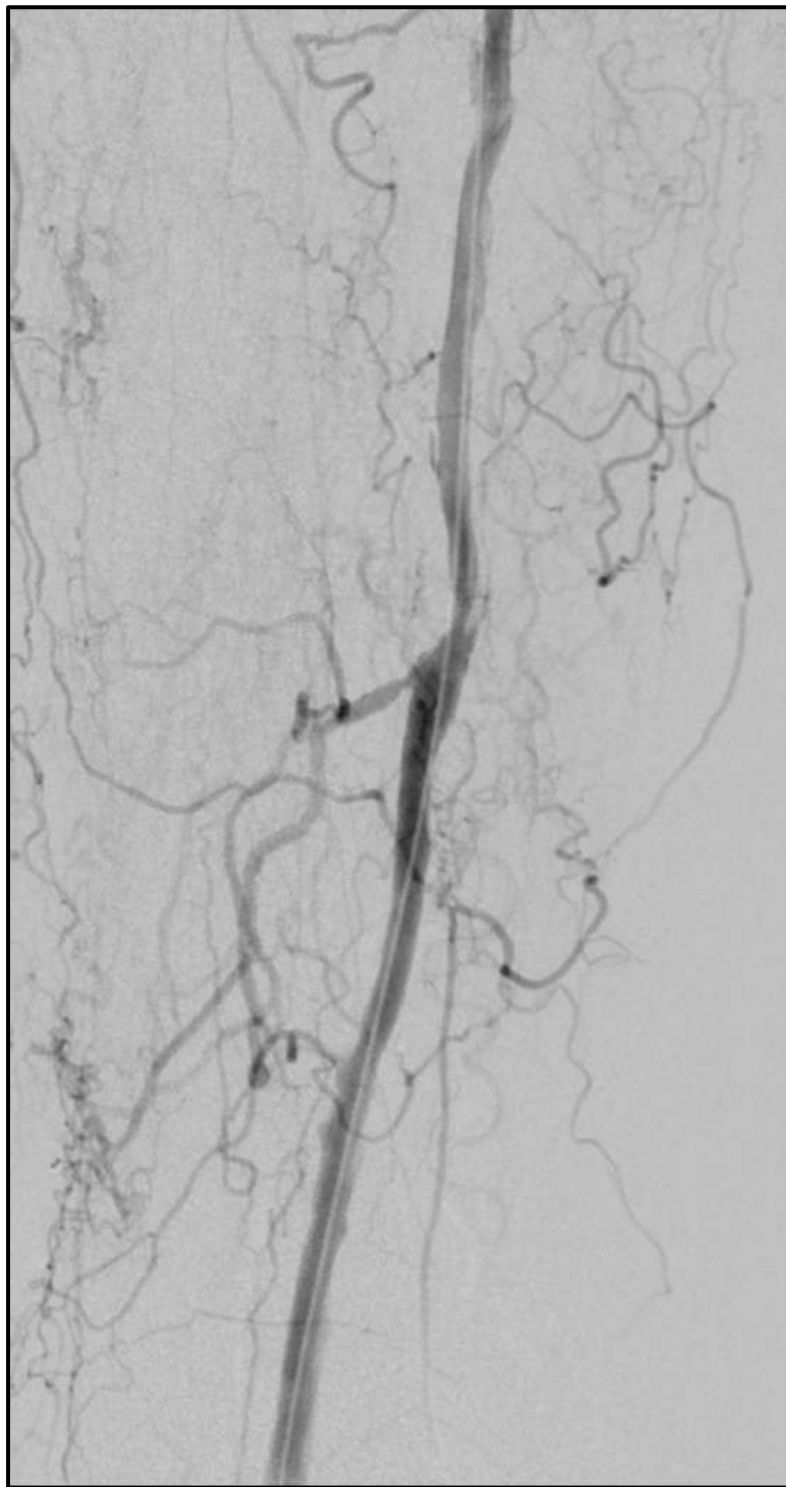
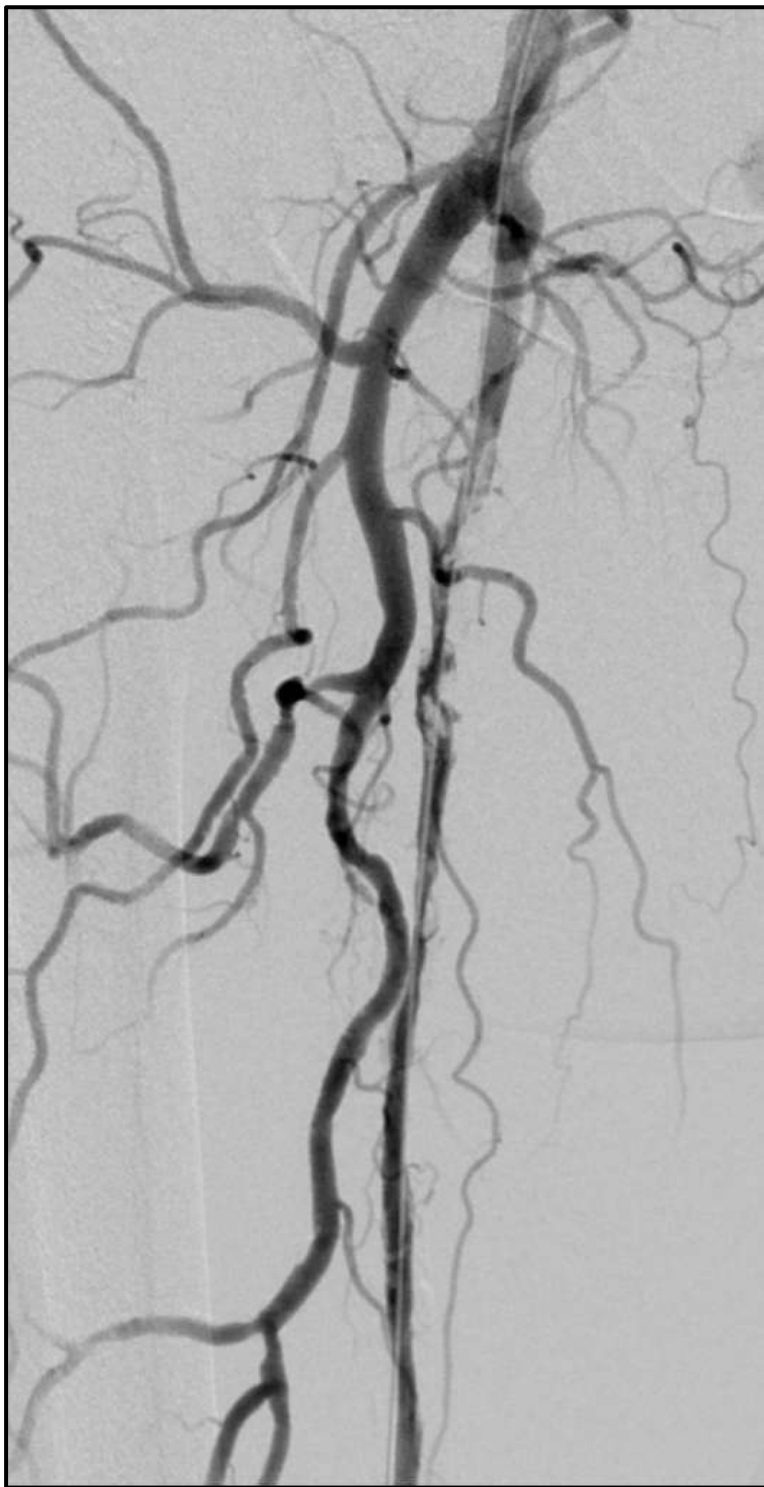
Barcelona 30<sup>th</sup> June /1<sup>st</sup> July 2022



Treatment Options:

BLUE: DCB

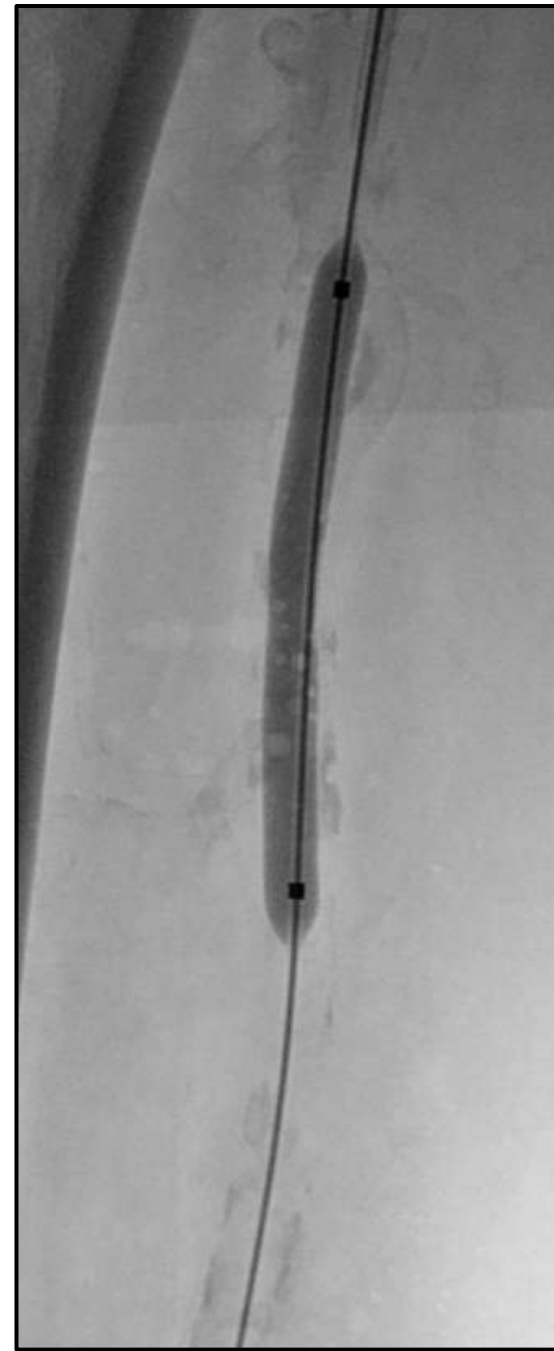
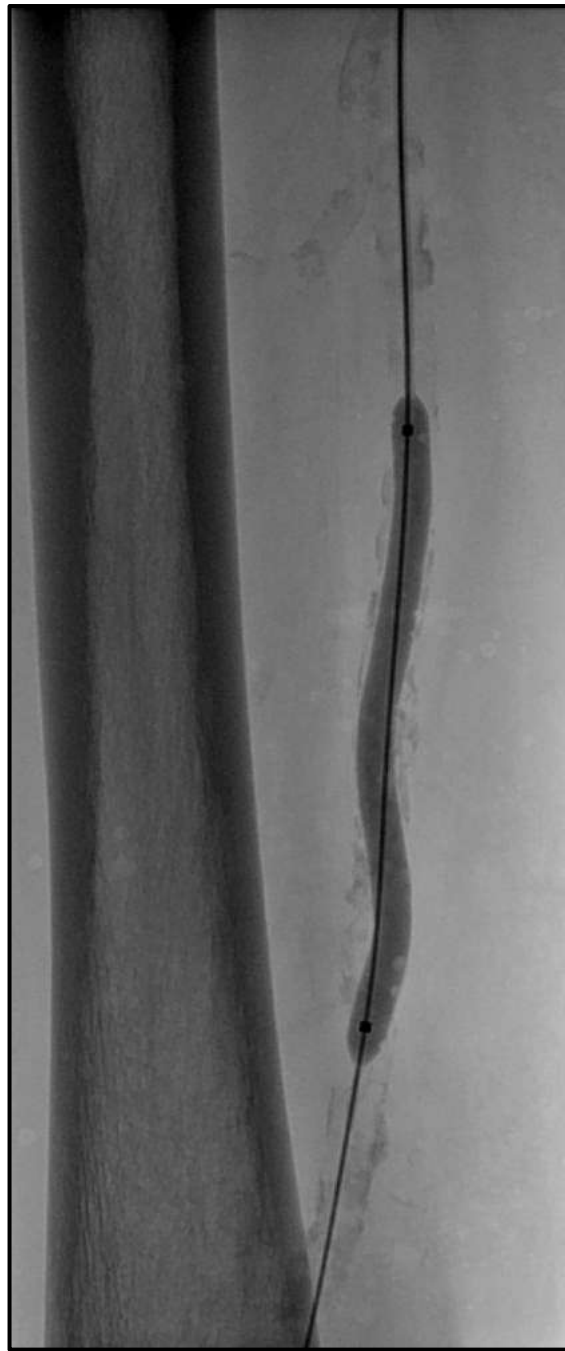
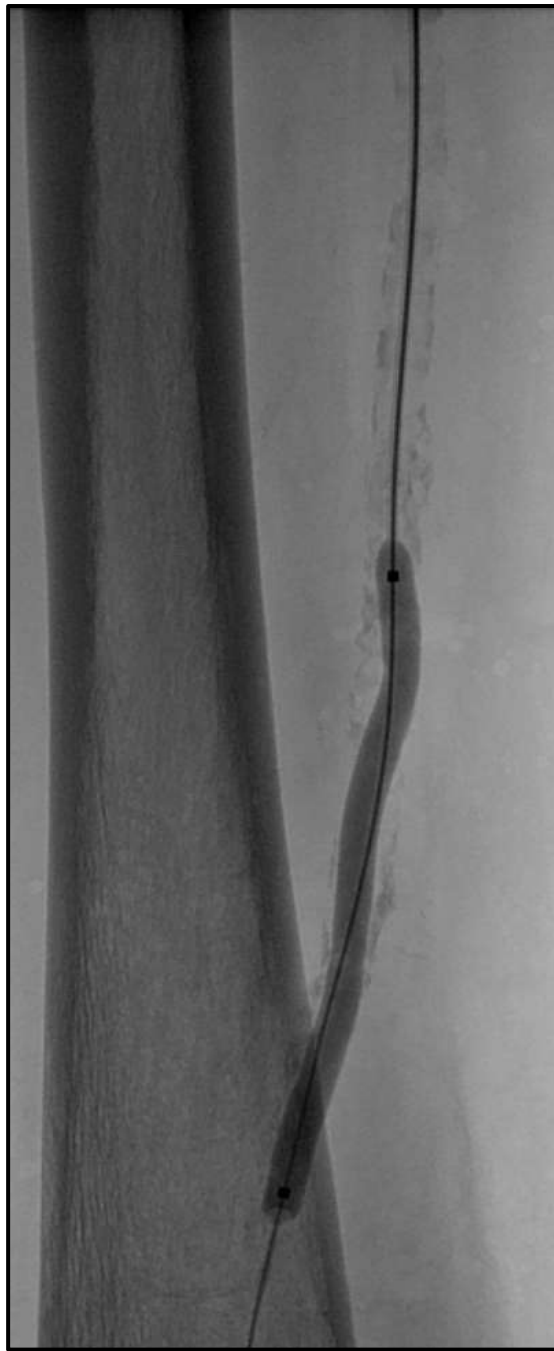PURPLE: STENTING



## Vessel Preparation:

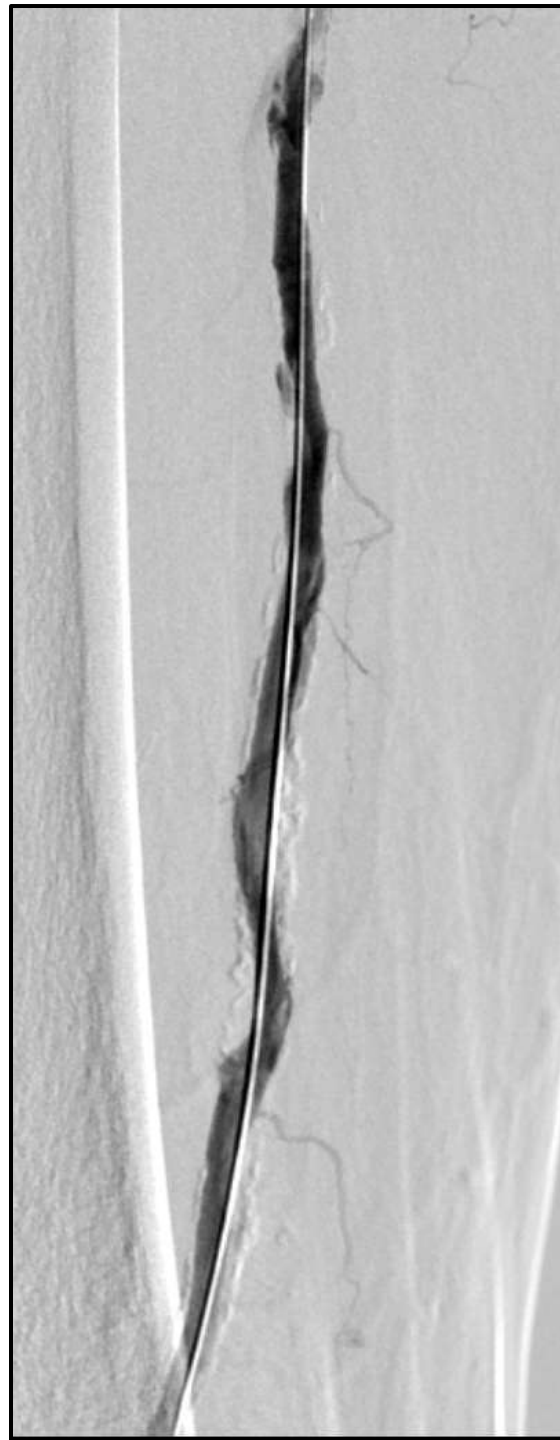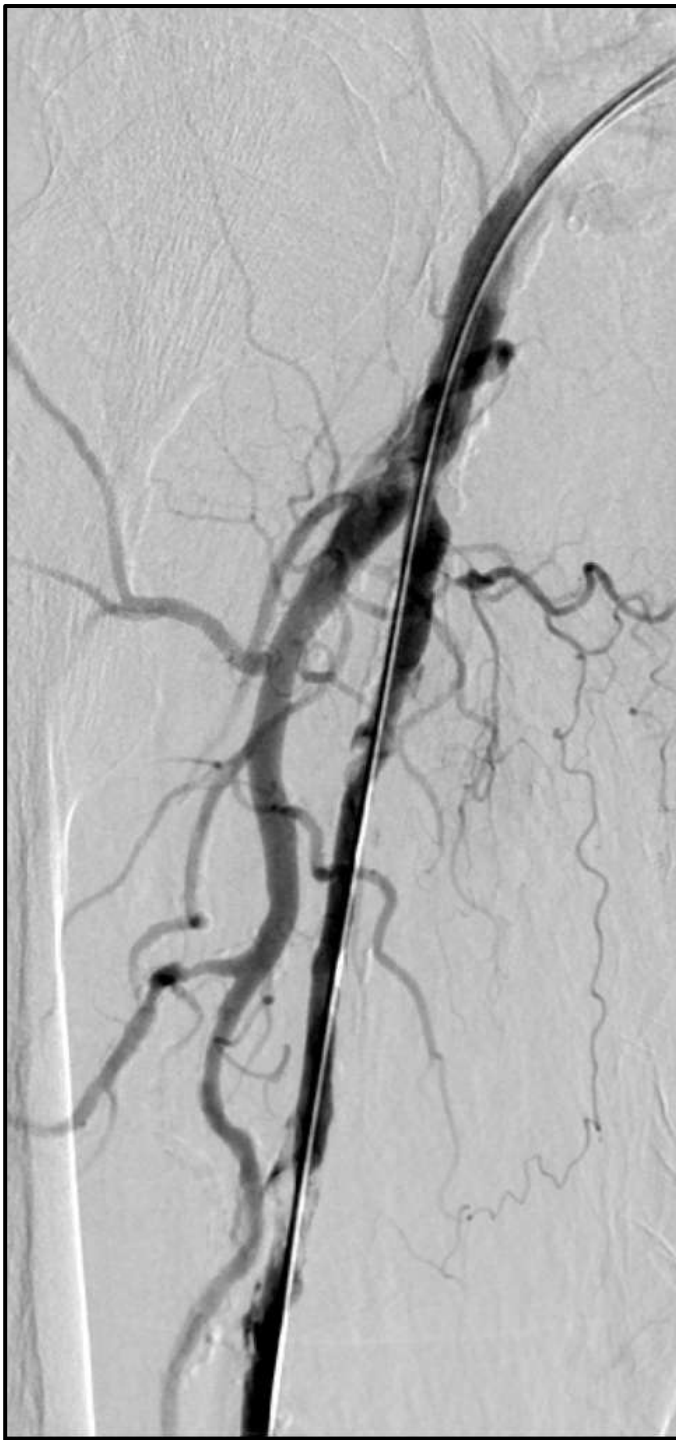BLUE: NO MORE ACTIONS

PURPLE: YES BETTER  
VESSEL PREP

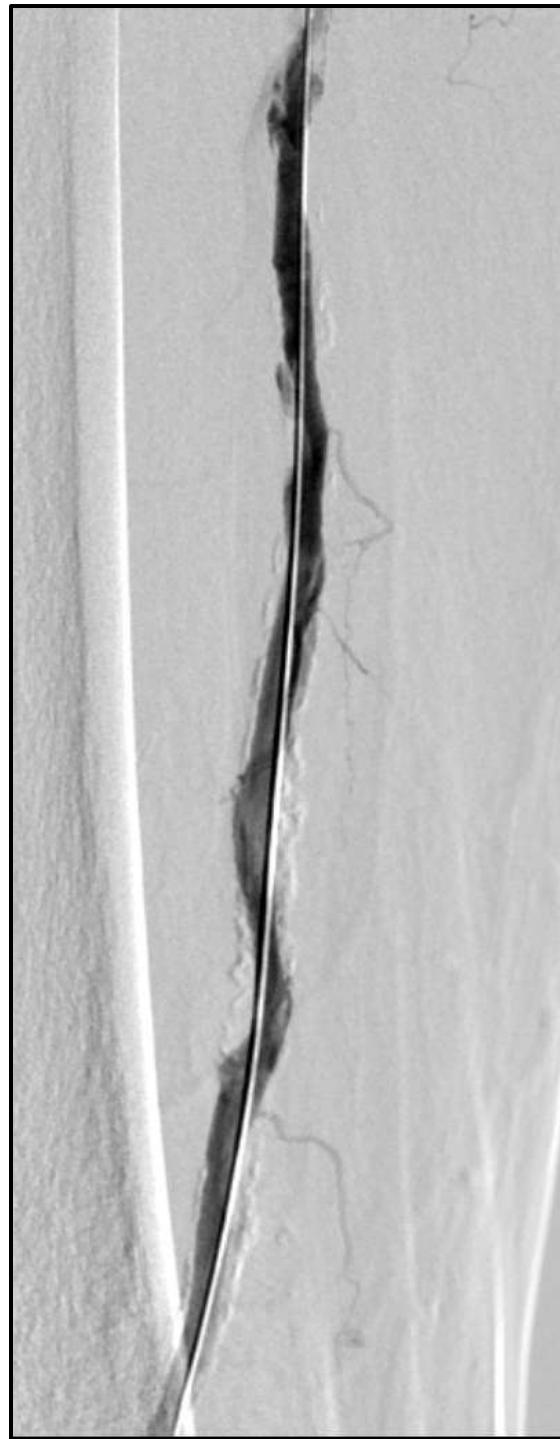
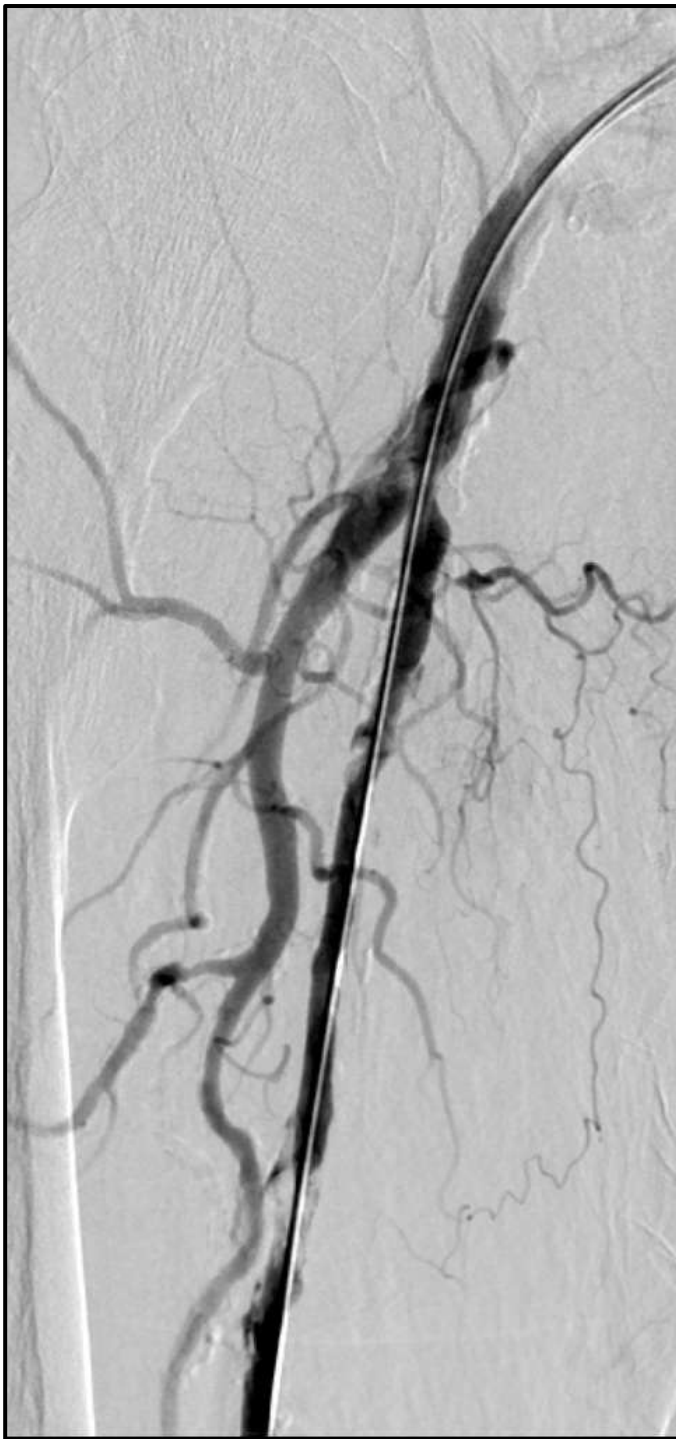
DCB 5 mm - Infl. Time >3 min.

Barcelona 30<sup>th</sup> June /1<sup>st</sup> July 2022







## FINAL ANGIO:

BLUE: I'M HAPPY,  
GOOD OUTCOME

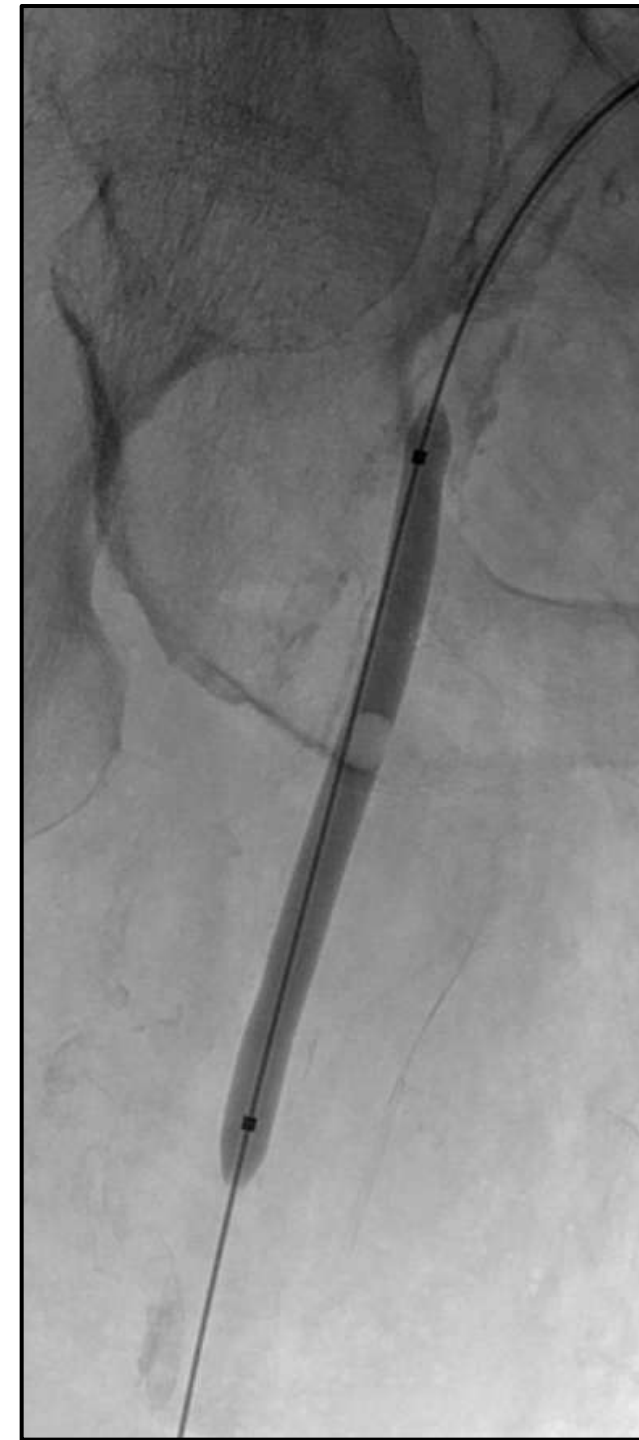
PURPLE: NO GOOD RESULT.  
DO MORE.....



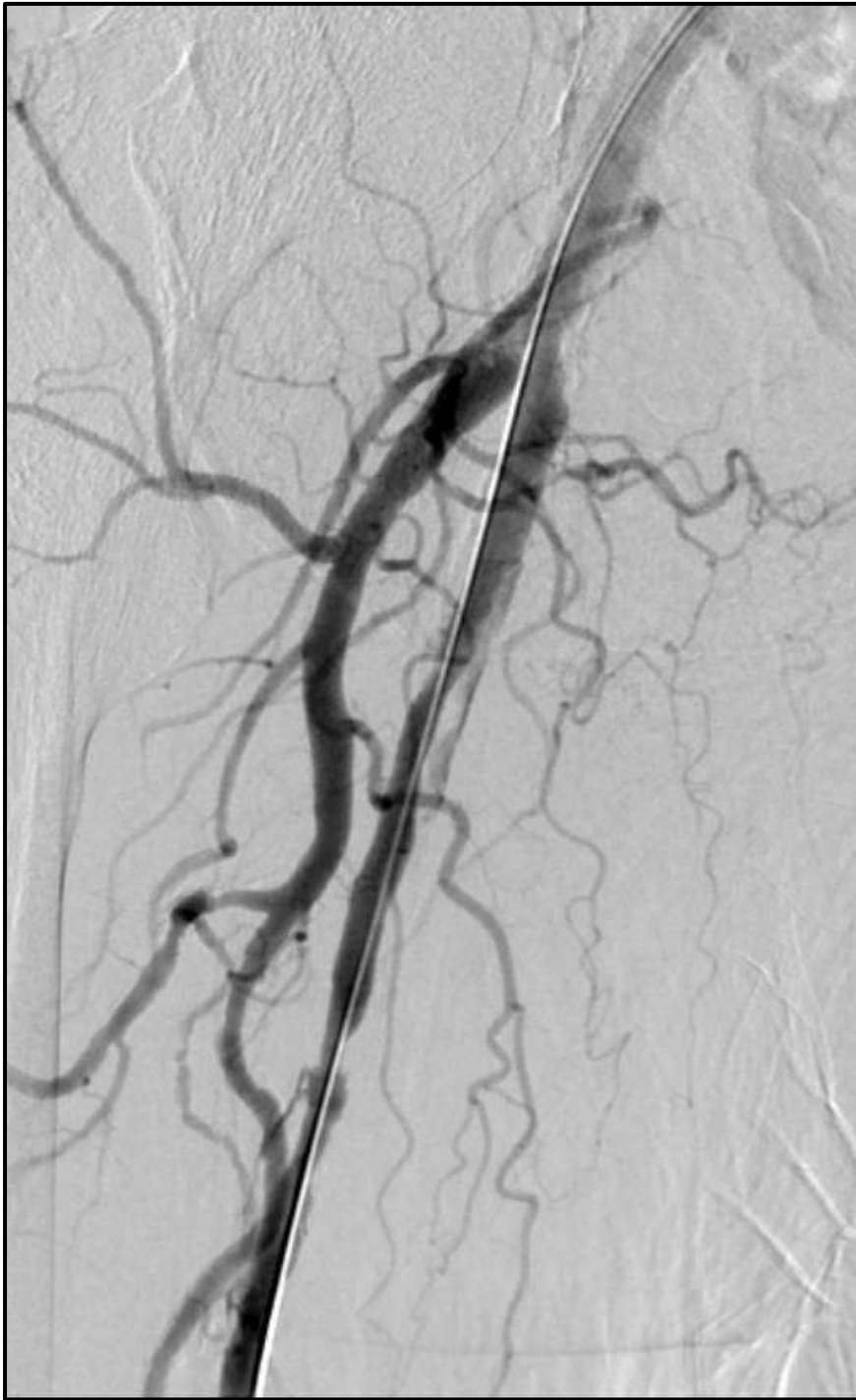
NEXT STEP:

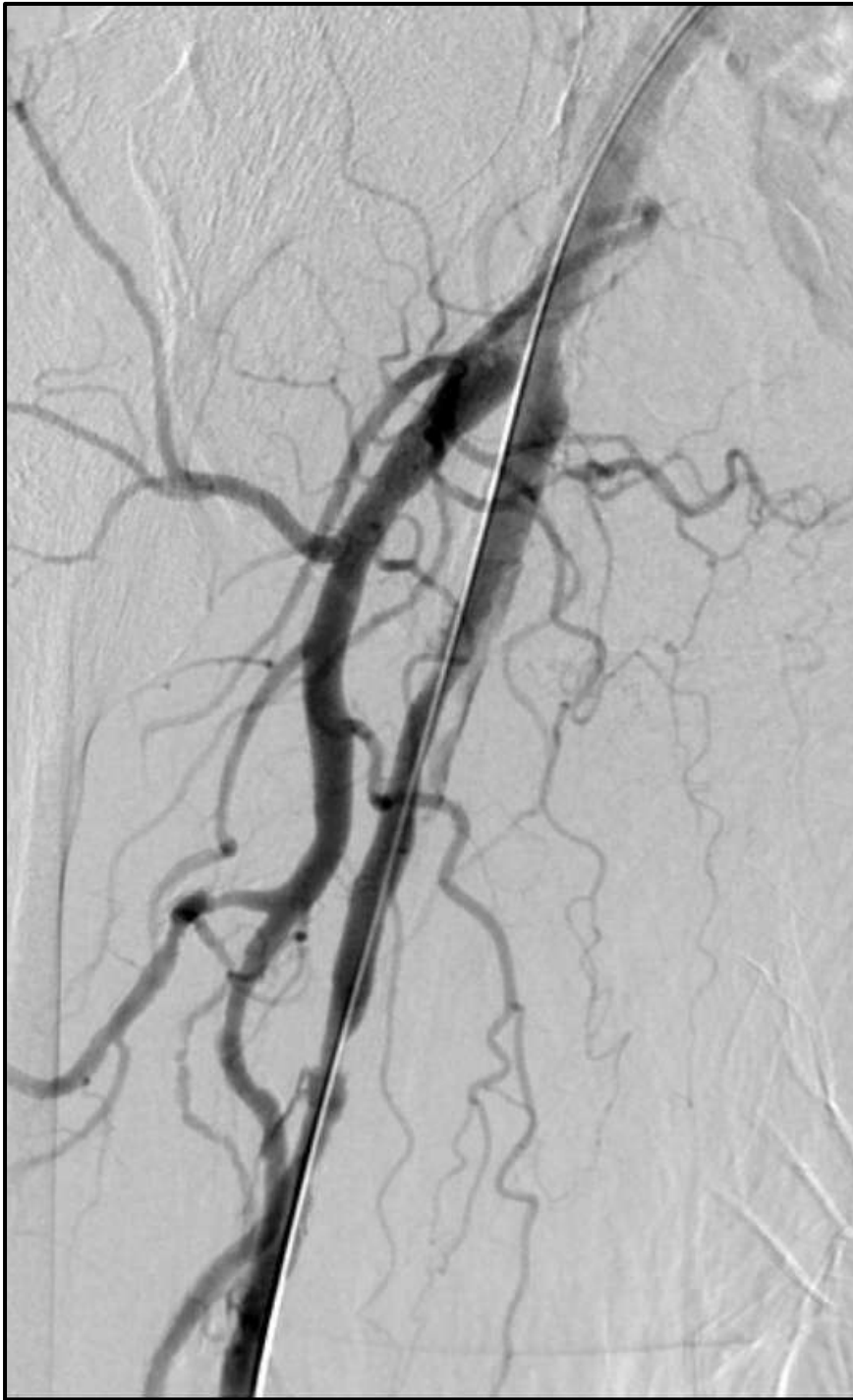BLUE: PROLONG PTA

PURPLE: STENTING



PTA  
5x60 mm  
Inf. Time 5 min

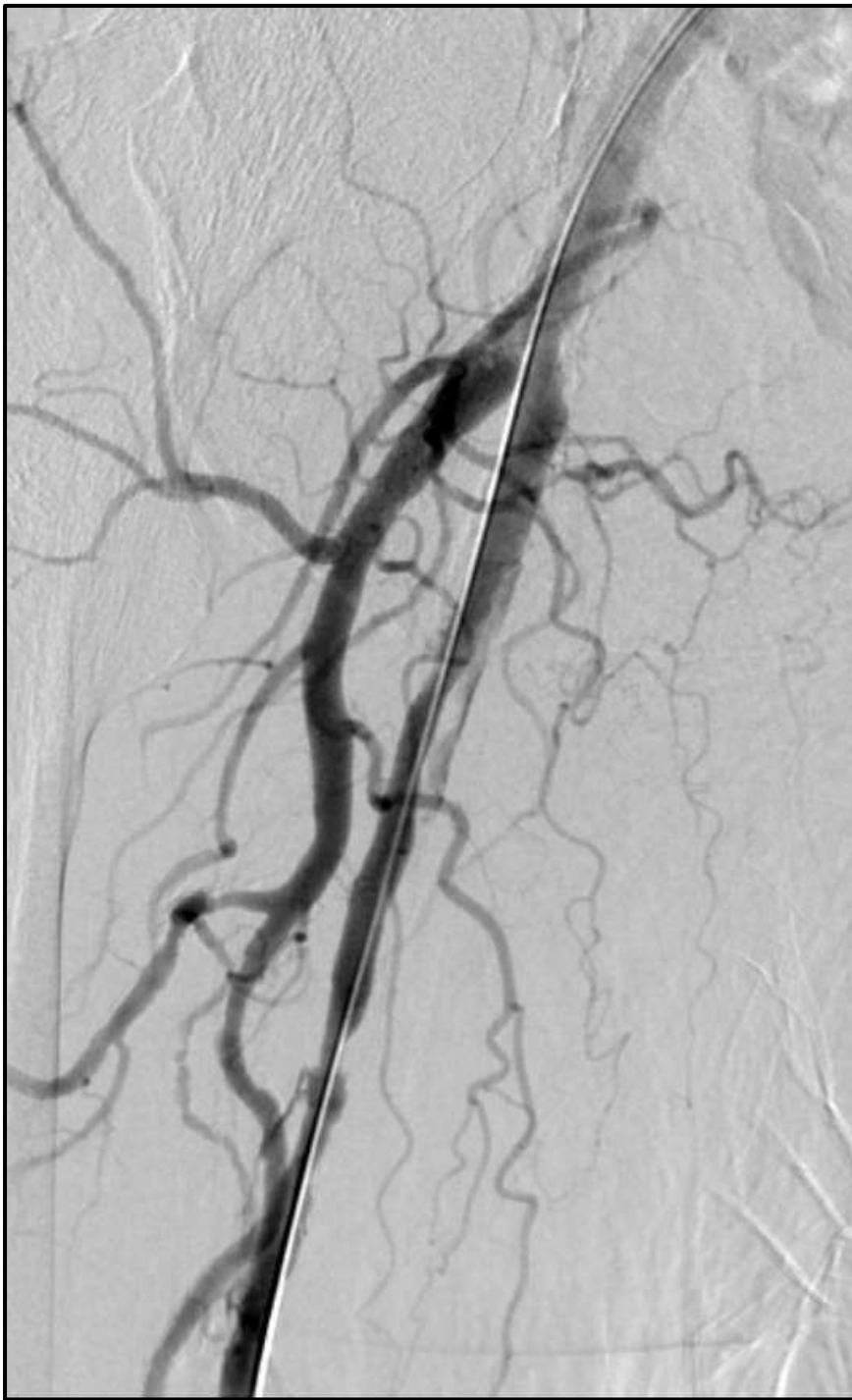



WHAT NEXT:

BLUE: DONE. WAIT AND SEE

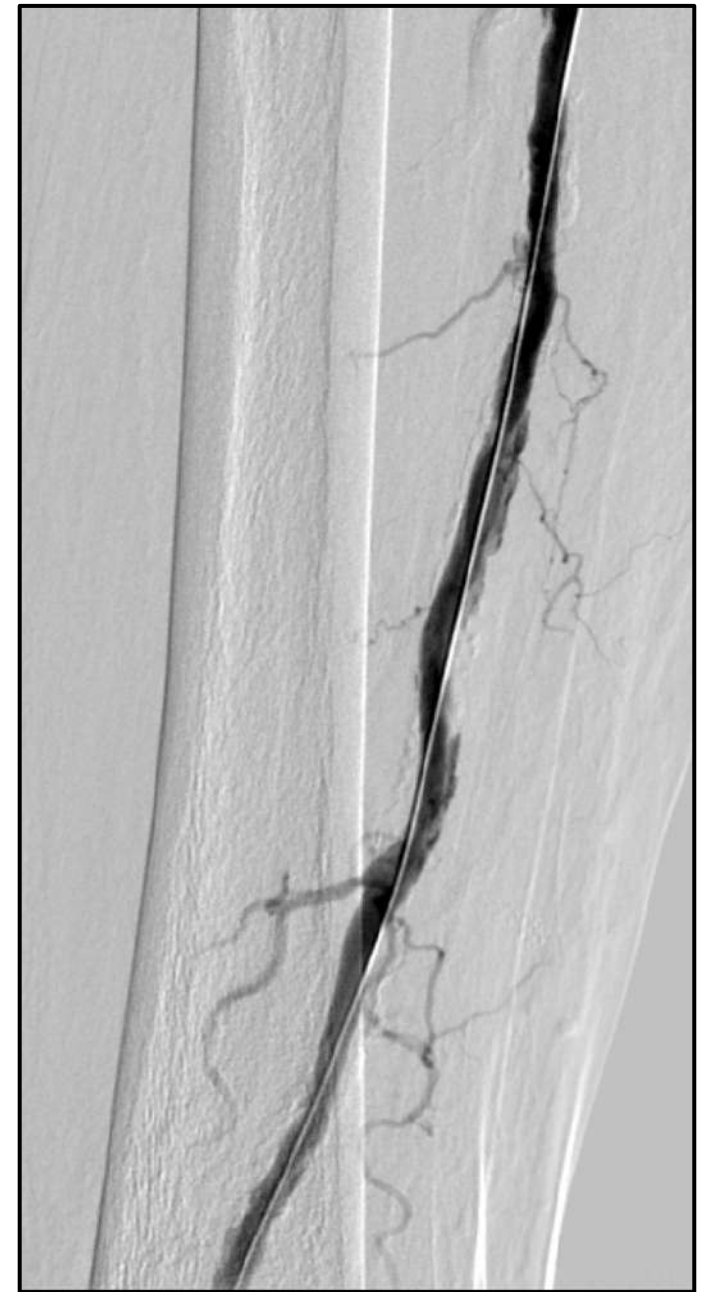
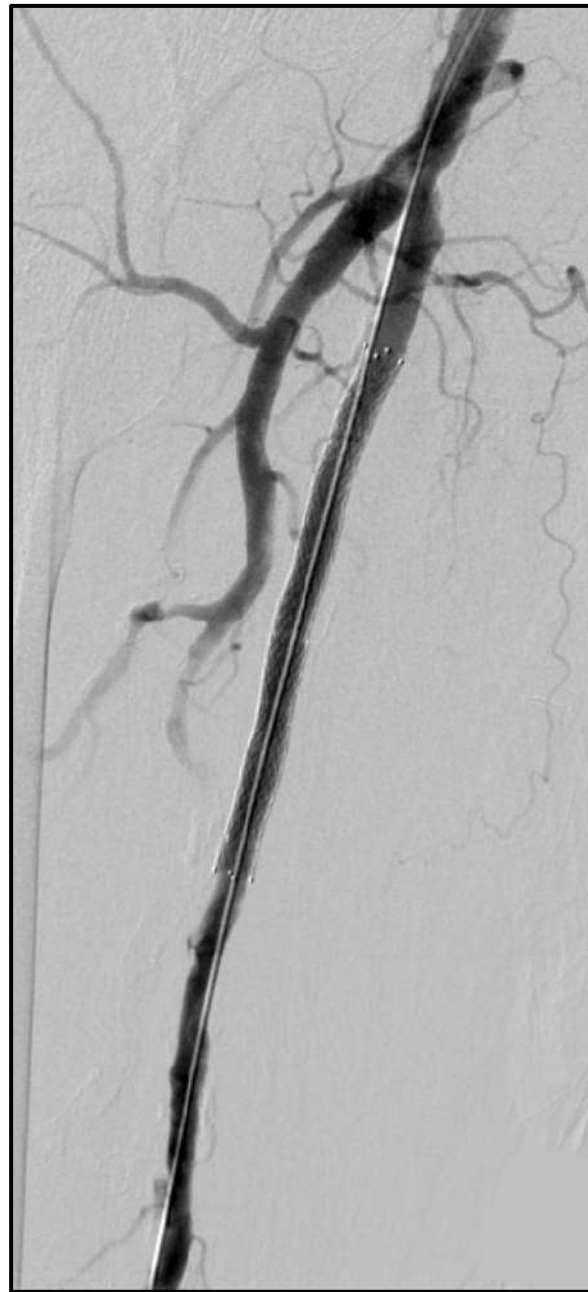
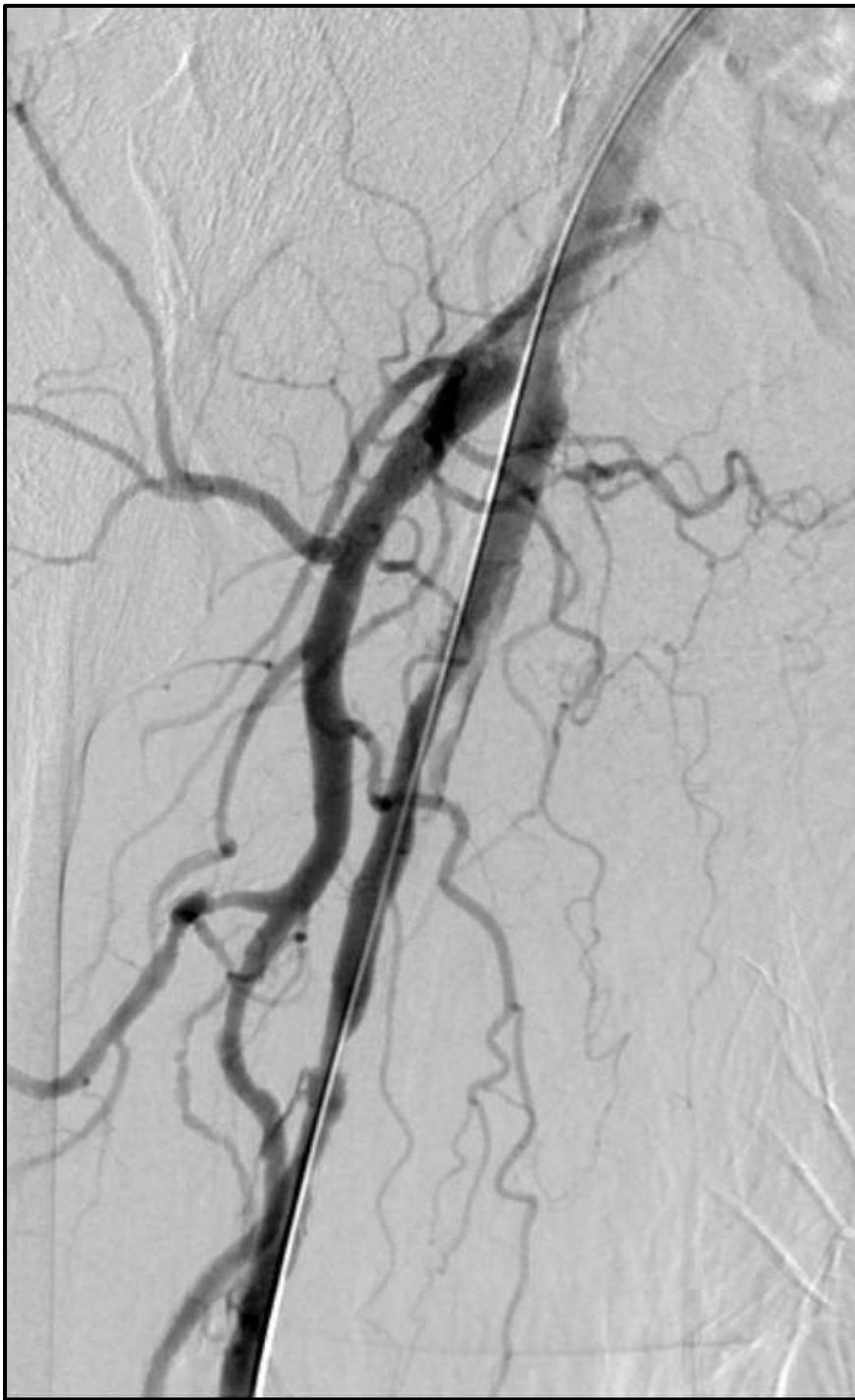PURPLE: MORE ACTIONS ARE REQUIRED




WHAT NEXT:

BLUE: PROLONG ANGIOPLASTY

PURPLE: STENTING

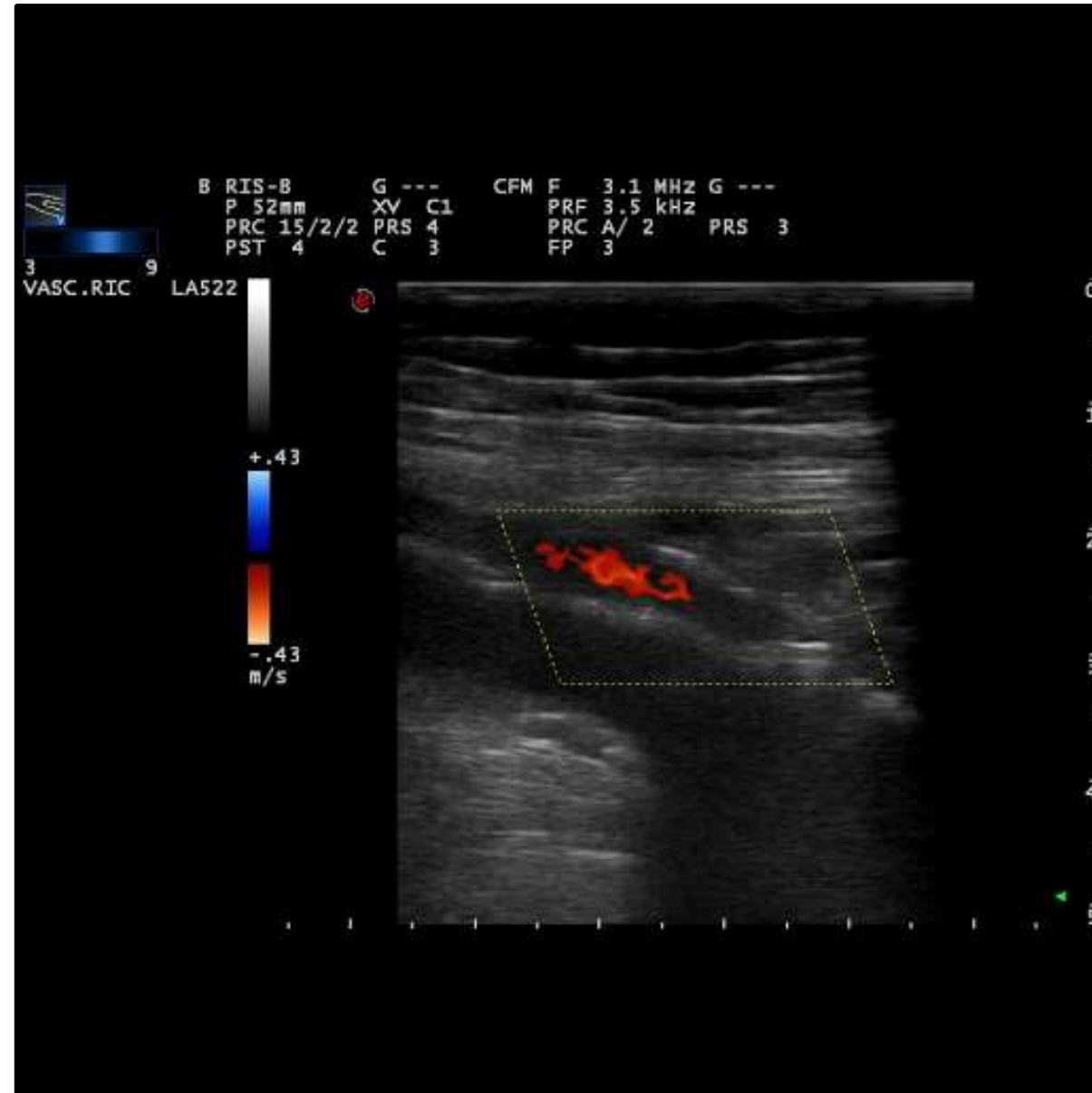

DES 6X100MM





5 Y. FU



Coming Soon

# Interventional Academy

To become an expert .....learn from the Experts !!!!!